



## PATIENT

Basil Marke

## SPECIES

Canine

## BREED

Boxer

## SEX

MN

## AGE

8 y

## WEIGHT

32 kg

## INTERPRETED BY

Keith Blass, DVM, MS,  
DACVIM (Cardiology)

## IMAGING PERFORMED BY

Dr. Judy McFarlen

## HOSPITAL NAME

Westview VH

## REFERRING VET

Dr. Parsons

## INVOICE

## DATE

3/12/26

## PRESENTING CLINICAL SIGNS

Grade 2/6 murmur. Pre-anesthetic evaluation (dental).

## ECHOCARDIOGRAPHIC FINDINGS

2D, M-mode, and Doppler study.

Left atrial size is normal. The mitral valve leaflets are mildly thickened, and a mild jet of eccentric mitral regurgitation is present. Left ventricular dimensions are normal. Left ventricular systolic function is normal. The aorta and aortic valve are normal. Right atrial and right ventricular dimensions are normal. The tricuspid valve leaflets are mildly thickened, and a mild jet of tricuspid regurgitation is present. TR velocity does not suggest the presence of pulmonary hypertension. The pulmonary artery and pulmonic valve are normal. No pericardial effusion or cardiac masses are seen.

ECG during echo: Sinus rhythm

LA - 41.8 mm  
LVIDd - 43.8 mm  
LVIDs - 32.7 mm  
FS - 25.3%  
RA - 32.4 mm  
LVOT - 1.70 m/s  
RVOT - 1.30 m/s  
TR - 2.74 mm/s

## ASSESSMENT/RECOMMENDATIONS

Degenerative mitral and tricuspid valve disease - stage B1

This examination demonstrates mild regurgitation of blood across Basil's mitral and tricuspid valves resulting from degenerative valve disease. The hemodynamic effects of the regurgitations also appear to be mild, as Basil does not have secondary dilation of any of his cardiac chambers, and his ventricular systolic function is normal. As such, Basil's current risk for the development of clinical signs secondary to his valvular diseases, such as coughing, exercise intolerance, syncope, labored breathing, and abdominal distension, appears to be low.

Basil's cardiovascular risk for general anesthesia is only mildly increased based on this exam, though I still recommend avoiding the use of alpha-2 agonists in the anesthetic protocol and reducing the IV fluid rate by 25% as precautions. If possible, monitoring of heart rhythm, blood pressure, and pulse oximetry are recommended during the procedure.

No therapy is recommended at this stage of Basil's valvular diseases.

A recheck echocardiogram is recommended in ~6 months to monitor for disease progression.



### PATIENT

Basil Marke

### SPECIES

Canine

### BREED

Boxer

### SEX

MN

### AGE

8 y

### WEIGHT

32 kg

### INTERPRETED BY

Keith Blass, DVM, MS,  
DACVIM (Cardiology)

### IMAGING PERFORMED BY

Dr. Judy McFarlen

### HOSPITAL NAME

Westview VH

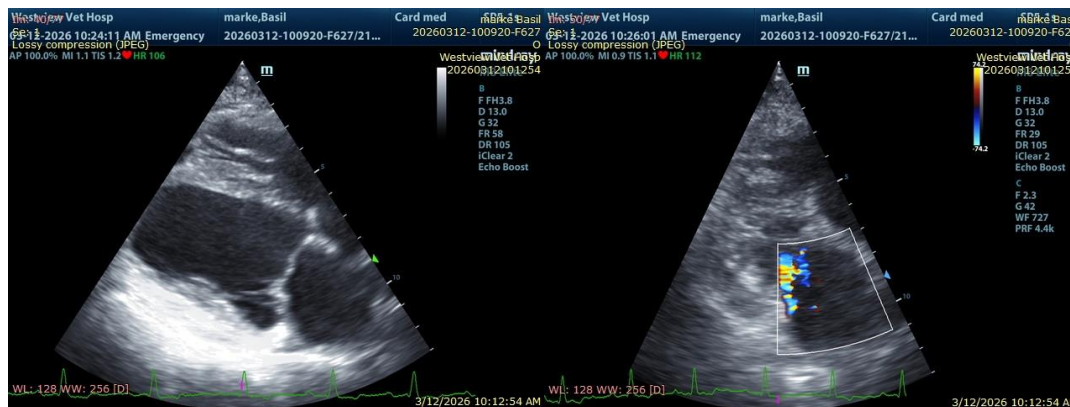
### REFERRING VET

Dr. Parsons

### INVOICE

### DATE

3/12/26



The information and recommendations provided are based on the images presented by the referring veterinarian/sonographer. No evaluation can be communicated regarding pathology that was not visible in the image/video clips provided.

Thank you for this referral. If the clinical or image interpretation does not parallel your findings or if I can be of any further assistance please contact me.

Keith Blass, DVM, MS, DACVIM (Cardiology) [info@SonoPath.com](mailto:info@SonoPath.com)